

# Remodeling Capacity of Femur Diaphysis Fracture with Non-Surgical Treatment in Preschool Children

## Remodeling Capacity of Femur Diaphysis Fracture

Savas Camur<sup>1</sup>, Bekir Eray Kilinc<sup>2</sup>, Haluk Celik<sup>3</sup>, Yunus Oc<sup>4</sup>, Osman Tugrul Eren<sup>4</sup>, Adnan Kara<sup>5</sup>

<sup>1</sup>Department of Orthopaedics and Traumatology, Umraniye Training and Research Hospital, Istanbul

<sup>2</sup>Department of Orthopaedics and Traumatology, Golhisar State Hospital, Burdur

<sup>3</sup>Department of Orthopaedics and Traumatology, Zonguldak State Hospital, Zonguldak

<sup>4</sup>Department of Orthopaedics and Traumatology, Sisli Etfal Training and Research Hospital, Istanbul

<sup>5</sup>Department of Orthopaedics and Traumatology, Istanbul Medipol University, Istanbul, Turkey

### Abstract

**Aim:** We aimed to evaluate the healing - remodeling capacities of femoral diaphysis fractures treated with non-surgical methods in preschool children.

**Material and Methods:** Thirty-six patients aged between 0-6 years with closed femoral diaphysis fractures who were treated with non-surgical methods were evaluated. Two-way graphics of the patients were taken after plastering. Limb lengths were recorded. Patients were divided into 2 groups according to their follow-up periods: 0-60 months (group A) and over 60 months (group B). The two-sided bilateral femoral graphics taken during their final examinations were used as the basis for radiographic evaluation.

**Results:** The mean age of the patients was 4.2±1.94 years. The mean amount of shortness of the patients measured when the plaster was removed was 1.61±0.84 cm and it was measured at a mean of 0.8±0.74 cm at the last follow-up. Angulation on the coronal and sagittal planes after treatment was significant ( $p<0.01$ ). The decrease in shortness is statistically significant ( $p<0.01$ ). Angulation improvement on the coronal plane in patients in group B was statistically significantly higher than in group A ( $p<0.05$ ). There was no statistically significant difference between groups A and B when the amounts of angular improvement on the sagittal plane were compared ( $p>0.05$ ).

**Discussion:** In our study we found that coronal plane deformities independent of the direction of joint movement continue remodeling at a statistically significant rate even after 5 years.

### Keywords

Femoral Diaphysis Fracture; Spica Cast; Traction; Remodeling; Femoral Healing

DOI:10.4328/ECAM.106

Received : 17.02.2017

Accepted : 27.02.2017

Published Online : 01.05.2017

Printed Online : 01.05.2017

Eu Clin Anal Med 2017;5(2): 17-20

**Corresponding Author:** Bekir Eray Kilinc, Golhisar Devlet Hastanesi, Burdur, 15400, Türkiye.

**GSM:** +90 530 606 18 84 - **E-Mail:** dreraykilinc@gmail.com

**How to cite this article:** Savas Camur, Bekir Eray Kilinc, Haluk Celik, Yunus Oc, Osman Tugrul Eren, Adnan Kara. Remodeling Capacity of Femur Diaphysis Fracture with Non-Surgical Treatment in Preschool Children. Eu Clin Anal Med 2017;5(2): 17-20.

## Introduction

Femoral diaphysis fractures, which constitute a significant share of childhood injuries, are caused by high-energy traumas [1]. Localization is most common in the middle third of the femur. Fragments can be displaced in different directions due to the pull of the muscles.

Femoral diaphysis fractures can be successfully treated with non-surgical methods in preschool children. Non-surgical methods are the first choice of treatment for fractures in this age group. Qualities such as the potential of the pediatric bone structure for rapid healing, the ability for spontaneous improvement of deformities, such as certain amounts of angulation and shortness, and thick periosteum increase the success of non-surgical treatment [2,3].

Among non-surgical treatment methods of childhood femoral diaphysis fractures are early plastering after closed reduction and late plastering following traction. Surgical treatment is considered for severely segmented fractures, cases with vascular nerve injuries, cases with head trauma and accompanying injuries, and cases with multiple injuries and open wounds requiring care [7-9].

In our study, we aimed to evaluate the healing - remodeling capacities of femoral diaphysis fractures treated with non-surgical methods in preschool children.

## Material and Methods

36 patients aged between 0-6 years with closed femoral diaphysis fractures who were treated with non-surgical methods in our hospital between 2001 and 2013 were studied.

A pelvipedal plaster was applied on the patients after various durations of traction done according to the amount of shortness and angulation. Two-way graphics of the patients were taken after plastering.

Fracture lines and fracture alignments were examined with graphics during examination of the patients. The appropriate type of traction was chosen according to the location of the fracture line, age of the patient, and the presence of accompanying injuries. Joint range of motion, limb length, and complaints regarding rotational deformity were recorded in the clinical examination. Limb lengths were recorded by measuring and comparing the distances between the anterior superior iliac spine and the medial malleolus.

The first plastered graphics of the patients, the bone union graphics at the moment the plaster was removed, and the two-sided bilateral femoral graphics taken during their final examinations were used as the basis for radiographic evaluation. The valgus-varus angulation was measured in the anterior-posterior femoral radiography and the anterior-posterior angulations were measured in the lateral radiography.

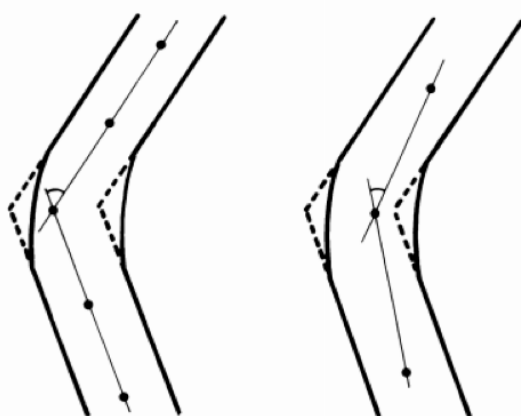


Figure 1. Measurement of angulation

Because local remodeling can lead to incorrect measurements, measurements were made at the intersection of lines drawn from two points selected from a distance of at least 3 cm from the fracture, on both sides of the fracture line (Figure 1).

Patients were divided into 2 groups according to their follow-up periods: 0-60 months (group A) and over 60 months (group B).

These 2 groups were compared in terms of remodeling according to the length of their follow-up period.

## Results

Two patients were treated with a pelvipedal plaster after skeletal traction, 14 patients were treated with a pelvipedal plaster after a Russell traction, and 20 patients were treated with a pelvipedal plaster after traction with a Braun's splint.

The mean age of the 36 patients was  $4.2 \pm 1.94$  years. 25 of the patients were male and 11 were female (Table 1).

When the femoral diaphysis fractures were classified according to the fracture line, it was seen that nine (25%) were transverse, nine (25%) were oblique, 14 (38.8%) were spiral, and 4 (11.2%) were comminuted fractures (Table 2).

When femoral diaphysis fractures were classified according to their fracture localizations, six (16.7%) were found to be in the proximal 1/3, 26 (72.3%) were found to be in the medial 1/3, and four (11%) were found to be in the distal 1/3 (Table 3).

The average duration of plastering was 5.6 weeks.

The follow-up period of the patients ranged from 11 to 137 months with a mean of  $61.88 \pm 36.81$  months.

Mean angulation on the coronal plane was found as  $13.6 \pm 7.2$  degrees and mean angulation on the sagittal plane as  $15.51 \pm 8.96$  degrees in the graphics taken at discharge of the patients. In the graphics taken at the final follow-up, mean angulation on the coronal plane was found as  $7.08 \pm 5.35$  degrees and mean angulation on the sagittal plane as  $9.04 \pm 5.14$  degrees (Table 4).

Table 1. Distribution by Age and Sex

Sex	0-2 years	2-5 years	≥6 years	Total
Male	5	15	5	25
Female	1	6	4	11
Total	6	21	9	36

Table 2. Classification of femoral diaphysis fractures according to the fracture line

Fracture line	Number of patients (percentage)
Transverse	9 (25%)
Oblique	9 (25%)
Spiral	14 (38.8%)
Comminuted, segmental	4 (11.2%)

Table 3. Classification of femoral diaphysis fractures according to fracture localization

Location of the fracture	Number of patients (percentage)
Proximal 1/3	6 (16.6%)
Medial 1/3	26 (72.3%)
Distal 1/3	4 (11.1%)

Table 4. Change of angulation from the end of treatment to final follow-up

	At removal of plaster	Final follow-up
Angulation on the coronal plane (degrees)	$13.6^\circ$ [4-31]	$7.08^\circ$ [0-26]
Angulation on the Sagittal plane (degrees)	$15.51^\circ$ [5-44]	$9.04^\circ$ [0-19]

The mean amount of shortness of the patients measured when the plaster was removed was  $1.61 \pm 0.84$  cm and it was measured at a mean of  $0.8 \pm 0.74$  cm at the final follow-up.

The change in the degrees of angulation on the coronal and sagittal planes after treatment was found to be statistically significant ( $p < 0.01$ ) (Table 5).

Femur shortness measurements after treatment varied and were measured to be an average of  $1.61 \pm 0.84$  cm ( $r: -3.5-0$ ), while they averaged  $-0.08 \pm 0.74$  cm ( $r: -1.5-2$ ) in the final follow-up measurements. The decrease in shortness is statistically significant ( $p < 0.01$ ) (Table 5). The follow-up periods of the patients ranged from 11 to 137 months with a mean of  $61.88 \pm 36.81$  months. 44.4% ( $n=16$ ) were in group A and 55.6%

**Table 5.** Assessment of the amount of change in angulation on the coronal and sagittal planes and shortness measurements

	Min-Max	Mean $\pm$ SD	Median	p
The amount of angulation on the coronal plane after removal of the plaster (degrees)	4-31	13.60 $\pm$ 7.20	11	0.001**
The amount of angulation on the coronal plane in the final follow-up (degrees)	0-26	7.08 $\pm$ 5.35	6.0	
The amount of improvement on coronal plane (degrees)	2-20	6.52 $\pm$ 4.35	5.0	
The amount of angulation on the sagittal plane after the removal of plaster (degrees)	5-44	14.60 $\pm$ 8.96	12.0	0.001**
The amount of angulation on the sagittal plane in the final follow-up (degrees)	0-19	9.04 $\pm$ 5.14	8.0	
The amount of improvement on the sagittal plane (degrees)	-11-26	5.56 $\pm$ 6.41	4.0	
Shortness after removal of plaster (cm)	-3.5-0	-1.61 $\pm$ 0.84	-1.5	0.001**
Final follow-up Shortness (cm)	-1.5-2.0	-0.08 $\pm$ 0.74	0	
Difference in Shortness	0-4.5	1.53 $\pm$ 1.17	1.50	
Wilcoxon Signed Rank test	** $p < 0.01$			

**Table 6.** Comparisons of the amount of angulation improvement on the coronal plane, amount of angulation improvement on the sagittal plane and amount of shortness improvement between measurements after plaster removal and at final follow-up and treatment period groups

Treatment Period		Amount of angulation improvement on the coronal plane (degrees)	Amount of angulation improvement on the sagittal plane (degrees)	Amount of shortness improvement (cm)
Between 0-60 months ( $n=16$ )	Average	4.82 $\pm$ 3.16	4 $\pm$ 6.07	1.39
>60 months ( $n=20$ )	Average	7.86 $\pm$ 4.79	6.79 $\pm$ 6.64	1.64
	p	0.046*	0.671	0.573
Mann-Whitney U Test	* $p < 0.05$			

**Table 7.** Comparison of the average amount of angulation improvement on the coronal plane, the average amount of angulation improvement on the sagittal plane, and the average amount of shortness improvement from the end of treatment to the final follow-up.

	Improvement between end of treatment and final follow-up	
	r	p
Average amount of angulation improvement on the coronal plane	0.465	0.019*
Average amount of angulation improvement on the sagittal plane	0.215	0.302
Average amount of shortness improvement	0.093	0.659
Spearman's correlation coefficient	* $p < 0.05$	

( $n=20$ ) were in group B.

The average amount of angulation improvement on the coronal plane in group A was  $4.82 \pm 3.16$  degrees, while in group B it was an average of  $7.86 \pm 4.79$  degrees. The amount of angulation improvement on the coronal plane in patients in group B was statistically significantly higher compared to those in group A ( $p < 0.05$ ) (Table 6).

In group A, the amount of angulation improvement on the sagittal plane was an average of  $4 \pm 6.07$  degrees, while in group B it was an average of  $6.79 \pm 6.64$  degrees. There was no statistically significant difference ( $p > 0.05$ ) between groups A and B when the amounts of angular improvement on the sagittal plane were compared (Table 6).

In group A, the average amount of shortness improvement was  $1.39 \pm 1.28$  cm, while in group B it was  $1.64 \pm 1.12$  cm. There was no statistically significant difference between groups A and B in terms of the amount of shortness improvement ( $p > 0.05$ ) (Table 6).

There is a statistically significant correlation between the amount of angulation improvement on the coronal plane and the treatment period ( $p < 0.05$ ) (Table 7).

There is no statistically significant correlation between the amount of angulation improvement on the sagittal plane and the treatment period ( $p > 0.05$ ) (Table 7).

There is no statistically significant correlation between the amount of shortness improvement and treatment periods ( $p > 0.05$ ) (Table 7).

## Discussion

Non-surgical methods should be preferred in the treatment of isolated femoral diaphysis fractures, which are common during preschool childhood (0-6 years). Qualities such as the rapid recovery potential of the pediatric bone structure, thick periosteum, and high remodeling capacity of deformities such as angulation and shortness increase the success of non-surgical treatment methods [2,3].

In childhood, the ability for remodeling depends on the fractured bone itself, the bone age of the patient, the proximity of the deformity to the joint, and the axis and orientation of the joint.

The upper extremities have more remodeling capacity than lower extremity bones. As the patient's bone age increases, the potential for residual growth decreases and therefore the capacity for remodeling decreases in direct proportion [7]. The distance of the deformity to the physis and the width of the physis are important factors in terms of remodeling. Closeness to the physis and a wide physis have a positive effect on remodeling [8].

Differences in limb length and angulation, which are among the problems encountered after treatment of femoral diaphysis fractures, are widely found in the literature. Poor angulation is more common, especially after proximal fractures. As the amount of angulation increases, it results in more permanent deformities [5,9,10].

In long bones, remodeling of the angulation typically occurs from the physis and diaphysis. 70-75% of the remodeling is from the proximal and distal physis of the fractured bone. The physis tries to correct the angulation by asymmetrically growing according to the loads on it [11,12]. Pauwels has shown that depending on the pressure changes on it, the physis can react by growing in different amounts in different parts [13,14]. Remodeling in the diaphysis occurs according to Wolff's law. The load increase on the concave side of the bone stimulates new bone formation on this side. The increase in tension on the convex side results in bone reabsorption in this region. 20-25% of remodeling occurs due to this new bone formation and reabsorption in the diaphysis [15]. Many studies have shown that deformities in the direction of movement of the neighboring joint improve more and that sagittal plane deformities in the femur and tibia improve more rapidly and leave less permanent deformity compared to coronal plane deformities [14,16,17].

In our study, we found that in patients whom we followed-up for more than 60 months, coronal plane deformities continued to remodel at a statistically significant rate, and that although sagittal plane deformities continued remodeling, this was not statistically significant. Thus, counter to the literature, we found that coronal plane deformities continued to remodel after 5 years.

Overgrowth is thought to occur due to overstimulation of the growth plates in the affected extremity as a result of hyperemia during the remodeling process. Because the increase in blood flow takes place throughout the extremity, the stimulation of growth in the tibia on the same side in femur fractures is more common but growth of the femur on the same side in tibia fractures is a rare occurrence [18].

While there are several opinions about how long the overgrowth lasts, Shapiro, who has one of the most extensive studies on overgrowth, reports that it peaks at the end of the 3rd month and generally ends at the 18th month in femur fractures [19]. Vijanto showed that the period of follow-up, rather than the age of the patient, is important in determining the overgrowth and that, in particular, overgrowth is statistically more significant in cases of over 10 years of follow-up [20].

The amount and period of overgrowth is a matter of debate, and in the group aged 2-10 years, shortness of up to 1.5-2 cm can be tolerated. Anderson, Griffin, and Green have stated in their study that they prefer the amount of overlay of broken fragments in patients aged 2-10 years not to exceed 1.5 cm and that this amount of overlay can be tolerated in this age group. However, they have reported that there was no similar amount of increase in growth in those under 2 years and in adolescents [2]. Malvaki reported that up to 15 mm of shortness improved with growth in his patients aged 2-10 years treated conservatively [15]. Ege et al. stated that 2 cm of shortness in children up to 8 years old and 1.5 cm shortness in children aged 8-12 years could improve with overgrowth and reported that end-to-end reduction is not necessary [21]. Lök et al. detected inequality in leg length measurements with clinical examination and orthoroentgenography and reported that initially a shortness of 0 mm was acceptable but that the ideal shortness is 10 mm [17]. In our study, the mean shortness, which was  $1.61 \pm 0.84$  cm after removal of the plaster, was calculated as  $0.08 \pm 0.74$  cm at the final follow-up, in accordance with the literature. The mean overgrowth of  $1.53 \pm 1.17$  cm between measurements was found to be statistically significant. Accordingly, our clinical experience indicates that when treating femur fractures, it may be necessary to allow for a certain amount of overlay, taking into account the patient's residual growth potential because of the risk of overgrowth.

Studies in the literature on rotational deformity in patients have not yielded meaningful results, so there is no consensus on the potential for remodeling of rotational deformities. Hagglund et al. have reported that no rotational deformities over 20 degrees were found in patients treated with traction methods [10].

Dauids has reported that in children with femoral diaphysis fracture, rotation deformity did not improve. However, they found that the soft tissues of the joint changed themselves so that the foot development angles would be symmetrical (conformity of the ligaments and joint capsules), that a wide hip range of motion (especially rotational movements) helped with this conformity, and that rotational deformities of up to 25° can be well tolerated, but that rotational deformities of more than 25° can give clinical signs [22].

Keskin et al. have reported reaching the conclusion that problematic rotational deformities requiring treatment following conservative treatment of childhood femoral diaphysis fractures were not a common complication [24].

No clinical complaints of rotational deformity were found in any of the patients in our study.

## Conclusion

The dominant view in the literature is that, with sagittal plane deformities of the femur in the direction of joint movement improving faster, the remodeling capacity of coronal plane deformities and shortness improvement is 5 years. In contrast to the literature, we found in our study that coronal plane deformities independent of the direction of joint movement continue remodeling at a statistically significant rate even after 5 years.

## Scientific Responsibility Statement

The authors declare that they are responsible for the article's scientific content including study design, data collection, analysis and interpretation, writing, some of the main line, or all of the preparation and scientific review of the contents and approval of the final version of the article.

## Animal and human rights statement

All procedures performed in this study were in accordance with the ethical standards of the institutional and/or national research committee and with the 1964 Helsinki declaration and its later amendments or comparable ethical standards. No animal or human studies were carried out by the authors for this article.

## Funding: None

## Conflict of interest

None of the authors received any type of financial support that could be considered potential conflict of interest regarding the manuscript or its submission.

## References

- Bombacı H, Ülkü K, Adıyke L, Kara S, Gorgec M. Childhood injuries, their etiologies, and preventive measures. *Acta Orthop Traumatol Turc* 2008;42(3):166-73.
- Griffin P, Anderson M, Green WT. Fractures of the Shaft of the femur. *Journal of Pediatric Orthop* 1972;3:213.
- Serin E, Yılmaz E, Belhan O. Çocuk Femur Cisim Kırıklarının Tedavi Sonuçları. *Hacettepe Ortopedi Dergisi* 2001;2:65.
- Einhorn TA. The cell and molecular biology of fracture healing. *Clin Orthop Relat Res* 1998;355:7-21.
- Campbell's Operative Orthopaedics 2007;2:1503-12.
- Kesemenli C, Subaşı M, Kırıköz T, Necmioglu S, Kapukaya A. Comparison of external fixation and pelvipedal cast treatments in closed femoral diaphysis fractures in children. *Acta Orthop Traumatol Turc* 2000;34:40-4.
- Kaye E. Principles of remodelling in children Wilkins 2009;6:123-38.
- Stilli S, Magnani M, Lampasi M, Antonioli D, Bettuzzi C et al. Remodelling and overgrowth after conservative treatment for femoral and tibial shaft fractures in children. *Chir Organi Mov* 2008;91(1):13-9.
- Hagglund G, Ingvar L, Olof N. Correction by growth of rotational deformity after femoral fracture in children treatment and results. *J. Orthop. Trauma* 1996;10:191-8.
- Wallace ME, Hoffman EB. Remodeling of angular deformity after femoral shaft fractures in children. *J Bone Joint Surg Br* 1992;75(5):7659.
- Gascó J, de Pablos J. Bone remodeling in malunited fractures in children. Is it reliable? *J Pediatr Orthop B* 2004;6(2):126-32.
- Murray DW, Wilson-MacDonald J, Morscher E, Rahn BA, Käslin M. Bone growth and remodelling after fracture *J Bone Joint Surg Br* 1996;78(1):42-50.
- Pauwels F. Biomechanics of the Locomotor Apparatus. Contributions on the Functional Anatomy of the Locomotor Apparatus 1982;135(2):442-3.
- Abraham E. Remodeling potential of long bones following angular osteotomies. *J Pediatr Orthop* 1989;9(1):37-43.
- Wolff J Das Gestz der Transformasion der Knochen. Verlag von August-Hirschwald. *Clin Orthop Relat Res* 2010;468(4):1047-9.
- Malkawi H, Shannak A, Hadidi S. Remodeling alter Femoral shaft fractures in children treated by the modified blount method. *J Pediatr Orthop* 1986;6:420-9.
- Lök V, Gölçüklü M, Öncü H. Çocuklarda femur kırıkları ve tedavisi. *EÜ Tıp Fak Mec* 1969;4:543.
- Reynolds DA. Growth changes in fractured long-bones: a study of 126 children. *J Bone Joint Surg Br* 1981;63(1):83-8.
- Shapiro F. Fractures of the femoral shaft in children. The overgrowth phenomenon. *Acta Orthop Scand* 1981;52:649-55.
- Vijanto J, Kiviluoto H, Paananen M. Remodelling after femoral fracture. *Açta Chir Scand* 1975;141:360-5.
- Perona PG, Light TR. Remodeling of the skeletally immature distal radius. *J Orthop Trauma* 1990;4(3):356-61.
- Dauids JR. Rotational Deformity and Remodelling after Fractures of Femur in Children. *Journal of Clinic Orthop* 1994;302:27-35.
- Brouwer KJ, Molenaar JC, van Linge B. Rotational deformities after femoral shaft fractures in childhood. A retrospective study 27-32 years after the accident. *Acta Orthop Scand* 1981;1:81-9.
- Keskin D, Ezirmik N, Tatlı L. Çocuk Femur Cisim Kırıklarının Konservatif Tedavisinin Bir Koplikasyonu Olarak Görülen Rotasyonel Deformiteler. *Ulusal Travma Derg* 2001;7:122-5.